

## OVARIECTOMY IN RODENTS CONTROL IN ESAS

Ana Silva Pereira<sup>1</sup>

<sup>1</sup>Instituto Politécnico de Santarém, Escola Superior Agrária de Santarém, Portugal

### RESUMO

No âmbito do control de ratos na Escola Superior Agrária de Santarém (ESAS) foram ovariectomizadas 16 gatas, para controlo de nascimentos.

Realizaram-se ovariectomias minimamente invasivas com eletrocoagulação. Não houve complicações intra ou pós-operativas. Ambos os ovários são de fácil acesso.

**Palavras-chave:** Ovariectomia minimamente invasiva, gatas, controlo de ratos.

### ABSTRACT

Within the rat control program in Escola Superior Agrária de Santarem (ESAS) were ovariectomized 16 female cats, as birth control.

A minimal invasive ovariectomy with electrocoagulation were performed. There were no intra- or postoperative complications. Both ovaries are easy to access.

**Keywords:** minimal invasive ovariectomy, female cats, rat control.

### INTRODUCTION

Since ancient Egypt the cats were used to catch the rats.

Today they are used again as an important tool (in organic agriculture, in Venice, in Zoomarine – [www.zoomarine.pt](http://www.zoomarine.pt), in Oeiras, Portugal).

To control their number, the females should be sterilized.

### MATERIAL AND METHODS

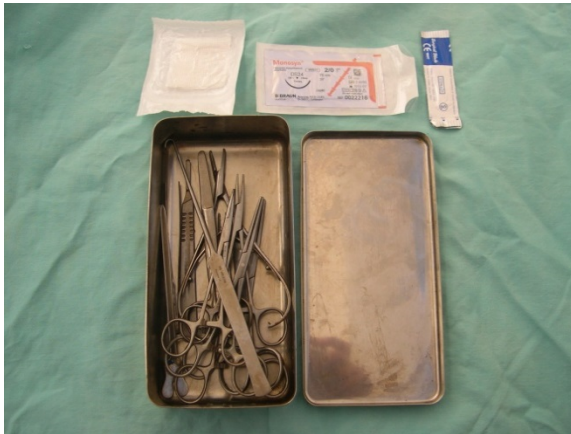In Escola Superior Agrária da Santarém (ESAS) the cats are also the main method of rats control.

To this purpose there are about 25 female and male cats in Quinta do Galinheiro and in Quinta do Bonito (the *campus* of the College).

Within the rat control program it was essential to maintain controlled the number of cats, especially to reduce the costs of animal feeding.

Otherwise, the non-use of rodenticides saves money and avoids spreading toxic products.

To assure birth control it was decided to ovariectomize the sixteen females. The material is seen in figure 1.



**Figure 1. Material**

As anesthetics were used ketamine and xylazine.

Then we describe the procedure in pictures.

The female were prepared for the operation - anesthesia, cut of the air, skin disinfection (figures 2 and 3).

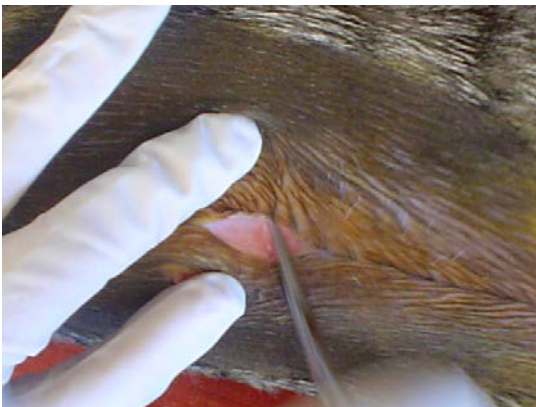


**Figure 2. Female cat prepared for the operation**

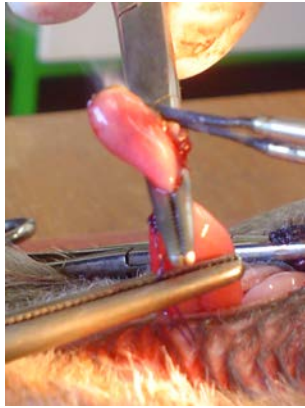


**Figure 3. The air cut and disinfection**

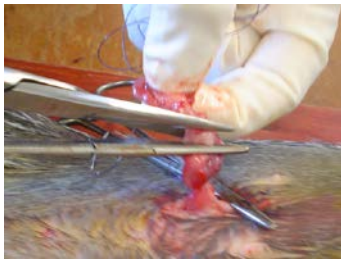
The skin is incised on just one centimeter. The ovaries are exteriorized with a pinch of ovaries, then isolated and removed with the aid of electrocoagulation and ligament sutures (figures 4, 5 and 6).



**Figure 4. The search of the ovaries**

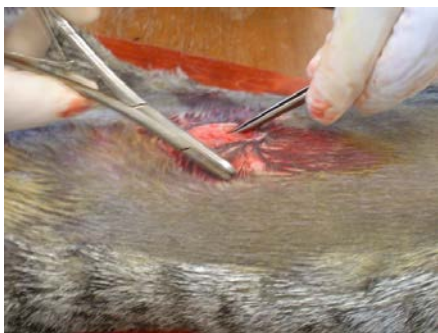


**Figure 5. The electrocoagulation**



**Figure 6. The cut of the ligament**

After that, the abdominal wall and skin are sutured (figure 7).



**Figure 7. The end of the operation**

To find out which females are operated we cut the tip of the left ear at the end of the operation (figure 8).



**Figure 8. The cut of the left ear**

## **RESULTS AND DISCUSSIONS**

The animals were not placed in the 10 degrees Trendelenburg position (head down) and no insufflation pressure were used.

The ovaries are easy to find and manipulate because of the long suspensory ligament. There were no intra- or postoperative complications, and there was no application of any drug preventively (for example antibiotic).

The duration of postoperative recovery was about 24 hours. After this period the animals were released.

## **CONCLUSIONS**

As a didactic point of view, it is important to show this procedure to the students, because it can be used in farms, cities and zoological gardens.

This technique should be performed by trained veterinary surgeons.

## **BIBLIOGRAPHIC REFERENCES**

[1]Borsong L., Chawhwu C., Lihseng Y., Liaw B.S., Chi C.H., Yeh L.S. Case report: retrospective study of long-term complications after spay surgery in dogs and cats. Taiwan Veterinary Journal 2003; 29(2):156-161.

[2]Toombs J.P., Clarke K.M. Basic Operative Techniques, in slatter D (eds): Textbook of Small Animal Surgery (ed.3). Philadelphia, PA, Saunders, 2003.

[3]Van Niemwegen S.A, Kinpenstein J. Laparoscopic ovariectomy in cats: comparasion of laser and bipolar electrocoagulation. J. Feline Med. Surg. 2007;9(5):397-403.